

## WINTER HOOF HEALTH & ABSCESS GUIDE

### SOUND YESTERDAY. LAME TODAY.

Few things are more concerning for horse owners than finding a horse that was completely sound yesterday suddenly hopping lame today. One of the most common causes of sudden lameness during the wetter months is a foot abscess.

Winter conditions can soften the hoof, weaken its natural protective barrier and increase the opportunity for bacteria to gain access through small cracks or defects in the hoof. The good news is that many foot abscesses respond very well to treatment once identified and managed appropriately.

### COMMON SIGNS

- ✓ Sudden severe lameness
- ✓ Heat in the foot
- ✓ Increased digital pulse
- ✓ Reluctance to bear weight
- ✓ Swelling around the pastern or lower limb

#### Pro Tip:

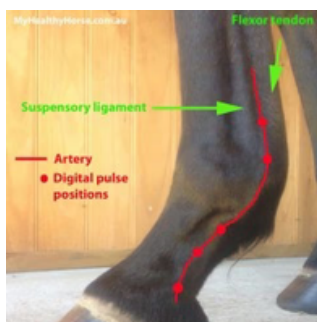
Many horses are completely sound one day and significantly lame the next.



### LEARN TO CHECK A DIGITAL PULSE

One of the most valuable skills horse owners can learn is how to check a digital pulse. A **normal digital pulse** is difficult to palpate as it represents the normal blood flow to the hoof. An **increased digital pulse** indicates increased blood flow to the distal limb (hoof) which can be one of the earliest signs of inflammation within the foot.

**Step 1:** Identify the landmarks on the leg



**Step 2:** Apply light pressure to the artery and assess strength of pulse with your index finger



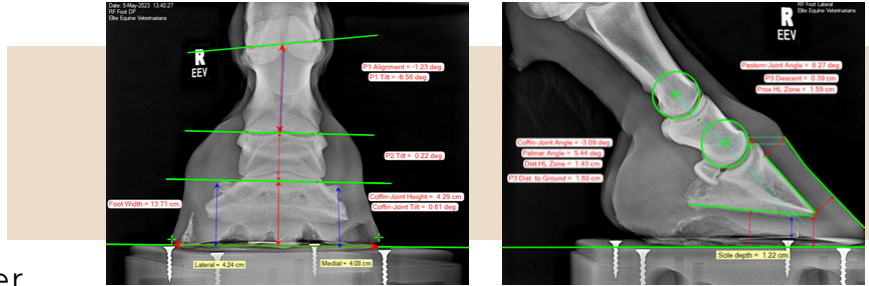
# WINTER HOOF HEALTH & ABSCESS GUIDE

## HEALTHY FEET START BEFORE AN ABSCESS

Good hoof health can help reduce the risk of many foot problems.

### Key Factors

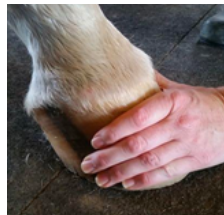
- ✓ Regular farrier care
- ✓ Good hoof balance
- ✓ Appropriate nutrition
- ✓ Healthy hoof growth
- ✓ Early identification of problems
- ✓ Monitoring feet during wet weather



## WHAT SHOULD YOU DO IF YOUR HORSE SUDDENLY BECOMES LAME?

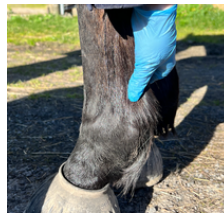### STEP 1

Restrict exercise and monitor your horse.



### STEP 2

Check for heat in the foot.



### STEP 3

Check the digital pulse.

### STEP 4

Contact your veterinarian or farrier if you're concerned.



### STEP 5

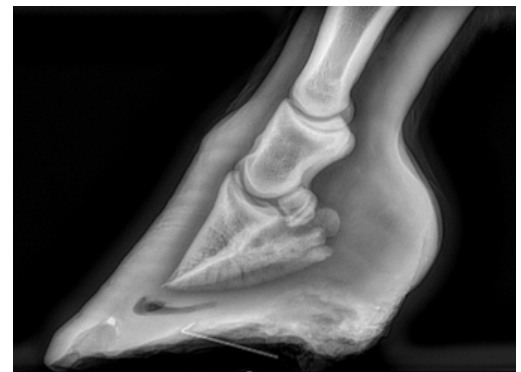
Avoid assuming every lame horse has an abscess.

## WHEN MIGHT X-RAYS BE RECOMMENDED?

Radiographs (X-rays) can sometimes help investigate:

- ✓ Recurrent abscesses
- ✓ Slow-to-resolve cases
- ✓ Ongoing foot pain
- ✓ Other causes of lameness

X-rays allow us to assess the hoof capsule and structures within the foot and help identify underlying problems that may require additional treatment.



## We're Here To Help

If you're concerned about your horse's feet, hoof health or sudden lameness this winter, our team is always happy to help.